A difficult case of post liver transplant rejection

Dr Hiruni Jayasena
Senior Registrar in Gastroenterology
CNTH

Mrs NB 38yr old

BMI 24.8kg/m^2

Blood group A+

Management Assistant, Chilaw

Mother of 2 children

Cause for cirrhosis : Chronic Budd-chiari syndrome

?AIH

Live donor LT : 23/07/2018 (India)

No post-op complications

Explant liver : Hepatic venous thrombosis with focal bridging fibrosis, nodularity and regenerative nodules. There is no evidence of AIH.

Co-morbidities: APLS (Anti-cardiolipin +) on warfarin

Timeline of events:

May 2019

Well, Normal LFTs

On Tacrolimus 2.5mg BD, MMF 500mg BD,

Pred 5 mg OD (continued post op)

September 2020

Well , AST 21, ALT 19, ALP 61, GGT 25, TB 0.57

Tac 2mg BD, MMF 500mg BD

C/o bone pain, had fracture in 2nd toe (Jan 2020) – wanted to come off Pred

Changed Pred to 2.5mg OD (to tail off slowly)

Tac Level 4.9

Jan 2021

? Advagraf 3mg BD dose taken by pt/ Compliance issues due to financial difficulties

AST 21, ALT 17.5, TB 0.79

Tac level 5.8

Medication adjusted: Pred 2.5mg EOD, Advagraf 3mg mane

Advagraf = extended-release Tacrolimus usually taken OD

Feb 2021

Well , AST 24.8, ALT 17.9, ALP 75, GGT 24.9, TB 0.71

Tac level 8

Medication adjusted to Advagraf 1mg BD, MMF 500mg BD, Pred 2.5mg EOD

April 2021

Well, off Pred since March 2021, on Advagraf 1mg BD, MMF 500mg BD

AST 21, ALT 27, ALP 61, GGT 27, TB 1.34, DB 0.4

High Tac level 12.3 –no toxicity features

For review with repeat Tac level in 1 week but Pt defaulted follow up

1st admission : 9th July 2021: Admitted with worsening pruritus & deranged LFTs

No recent meds/ precipitants

Not had blood test for 3/12

TAC level 8.1

On

Tac 1.5mg BD,

MMF 500mg BD

Off Prednisolone

Due to unavailability of Advagraf , Pt had switched to Prograf (Tac) in May 2021 on own.

	April 2021	9th July Admission	18 July Discharge
AST	21	249	201
ALT	27	279	217
ALP	61	302	222
GGT	27	570	389
TB	22.9	23	66.1
DB	6.8		
INR		4	5.3

Ix

- Hep A/B/C negative, ANA+ (>1:80), CMV IgG +ve
- **USS abdomen:** fatty liver grade 1-2
- **USS Doppler:** normal study
- **Liver biopsy done 18/7**

Clinically improved

<u>Discharged on Tac 1.5mg BD, Increased MMF 750mg BD</u>

HISTOPATHOLOGY REPORT

Specimen : Liver biopsy

Macroscopy : Three linear cores measuring 17mm, 15mm, 15mm and 1mm.

Microscopy : There are three cores of liver tissue with 14 portal tracts. The portal tracts are expanded by a moderate mixed inflammatory cell infiltrate predominantly comprising of lymphocytes, neutrophils occasional plasma cells, eosinophils and rare lymphoblsts (sore 2). There is a mild spill over of the inflammation into the peri portal parenchyma in some of the portal tracts. Bile ducts are noted and most of the ducts are infiltrated by inflammatory cells with some showing degenetaive changes (score 2). No ductopenia is present. Mild subendothelial lymphocytic infiltration involving some of the portal and central veins (score 1) is noted. There is a mild lobular inflammation and no evidence of confluent necrosis. Steatosis is noted amounting to 10% of the hepatocytes. Mild hepatocellular cholestasis is noted. But there is no canalicular cholestasis or bile infarcts are present. Occasional mild mixed inflammatory cell infiltration is noted in sinusoidal spaces with kupffer cell hyperplasia. Features are compatible with acute cellular rejection mild in severiry. No dysplasia or a malignancy is seen.

Conclusion : Liver biopsy -

Features are compatible with acute cellular rejection.

Rejection activity index (Banff Scheme for grading liver allograft rejection) - 5/9 (Mild).

Portal inflammation (2/3), Bile duct inflammation damage (2/3) and venous endothelial inflammation (1/3)

2nd admission: 21st July 2021
Pruritus with rising AST/ALT

Pulsed with Methyl pred 500mg daily
3 doses given.

Medication:
Tac 1.5mg BD, MMF 500mg BD, Pred 40mg OD, Cotrim 960mg 3x wkly, Valganciclovir 900mg OD

Symptoms improved
Discharged 26/7/21

	April 2021	July 9th	July 18th	21/7	22/7	23/7	25/7	26/7
AST	21	249	201	69	77	74	161	115
ALT	27	279	217	94	96	94	115	127
ALP	61	302	222	157	132	171	143	173
GGT	27	570	389	205	214	237	206	283
TB	22.9	23	66.1	106	99	88	78	91
DB	6.8			58	52	64	56.5	63
INR		4						

Methyl pred Pulse given

3rd admission: 3/8/2021 - Pruritus with rising AST/ALT

	4/8	5/8	6/8	7/8	8/8	9/8	11/8	12/8	13/8	15/8	16/8	18/8	20/8	22/8	23/8	24/8	25/8
AST	**289**	**250**	**176**	**160**	**164**	**255**	**261**	**321**	**351**	**303**	**237**	**236**	**286**	**327**	**337**	**300**	**254**
ALT	**446**	**364**	**337**	**336**	**306**	**367**	**400**	**470**	**520**	**498**	**375**	**385**	**405**	**487**	**509**	**451**	**398**
ALP	138	119	99	112	121	107	92	117	133	110	127	129	125	142	134	123	109
GGT	316	255	246	261	254	273	290	334	385	351	292	311	364	427	440	354	410
ALB	3.1	2.7	2.6	2.8	2.6	2.4	2.4	3	3	2.8	3.7	2.9	2.8	3	3	2.7	2.7
GLOB	2.5	2.2	2	2.2	2.2	2.1	2	1.9	2.3	2.1	1.3	2.4	2	2.4	2.5	1.9	2.1
TB	**140.6**	**125.6**	**170.6**	**96.7**	**133.4**	**180.2**	**167.4**	**163**	**161.4**	**142.2**	**193.6**	**146**	**109.7**	**121.1**	**143**	**158.5**	**117.7**
DB	**107.5**	**96.9**	**129.7**	**128**	**103.3**	**125.5**	**87.4**	**103**	**149.7**	**109**	**121.5**	**143.3**	**85.3**	**91.3**	**133.6**	**83.8**	**91.9**
Cr	58	52	96	47	89	71	61		54	59	49	78	46	43	50	65	44
CRP	<5	<5	<5	7	<5	<2	<2		<5	8	<5	6	<2	<5	5	<5	<5
S. Na	137	137	133	134			135	136	135	135	137		133	135			132
S. K	4.3	4.1	3.9	4.0			4.9	5.5	4.2	4.4	4.2		4.3	5			4.2
INR	1.79	1.43	2.54	5.64	7.72	2.19	1.29	4.47	10.2	3.65	1.74	2.27	6.4		2.4		
PT	20	15.8	28	54.9	73.05	23.3	14.4	49.5	95.7	37	19.6	24.4	70.3		21.3		
Hb	11.5	12.4	11.5	11.7		11.34	11.5	13.0	13.1	11.9	10.8	11.5	11		11.7	11.4	10.9
WBC	15.92	13.29	14.47	12.89		8.89	8.37	8.74	8.9	8.3	9.66	6.93	6.57		7.93	7.7	7.19
PLT	183	191	186	194		183	223	187	257	182	180	173	171		152	140	151

Methyl pred 1g pulse + NAC infusion given

Tac 1.5mg BD, MMF 500mg BD, Pred 40mg OD continued

Ix

TAC Level 9.3

CMV PCR -ve, EBV IgM –ve, HSV PCR -ve

USS Doppler 6/8/21: liver slightly coarse echogenicity, hepatic artery flow normal, no PVT, No thrombosis in hepatic vein but typical flow pattern not identified

CECT abdo 6/8/21: There is a significant luminal narrowing at the origin of hepatic artery. Small hypoechoic area in resection margin. Focal narrowing at the origin of hepatic artery at arterial anastomotic site

MRCP (6/8/21): Normal study

Repeat USS Doppler 13/8/21: normal morphology and Doppler study of transplanted liver with normal HV PV HA flow, no intra or extrahepatic collection

Liver biopsy repeated 16/8/21

2nd Liver biopsy

16/8/21

HISTOPATHOLOGY REPORT

Specimen : Liver biopsy

Macroscopy : Received three linear cores of green and tan colour tissue, measuring 18mm, 18mm and 15mm.

Microscopy : Sections show only two complete portal tracts, which are expanded by a mixed mononuclear cell infiltrate. The portal tracts show dystrophic/ damaged bile ducts. There is evidence of endotheliitis. Therefore there is a moderate - severe degree of acute cellular rejection. Rejection activity index (Banff Scheme) - 7/9. There is extensive perivenular cholestasis with associated hepatocytes injury with hepatocytes showing extensive ballooning and reticular degeneration. Associated inflammation is mild. This is a harbiinger of chronic rejection and duct damage. There is Kupffer cell hyperplasia, but sinusoidal lymphocytisus is is not marked.
Hence the histological features are compatible with acute cellular rejection with a possible degree of chronic rejection or impending chronic rejection as indicated by the extensive perivenular cholestasis that is present.
It is difficult to assess ductopenia as there are only two portal tracts evident.

Conclusion : Liver biopsy -
Acute cellular rejection with possible degree of chronic rejection impending chronic rejection
Rejection activity index (Banff Scheme) -7/9.

Management of a post liver transplant patient in chronic rejection.

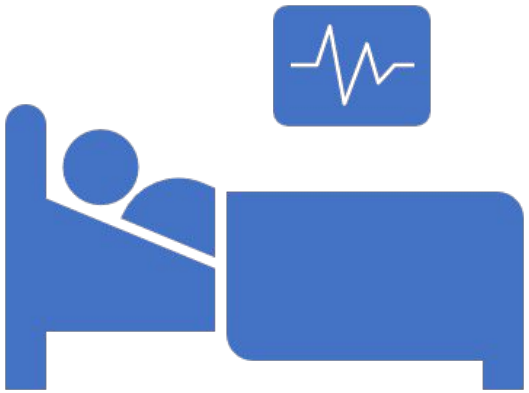

Allograft rejection

Hyperacute rejection

Acute cellular rejection

Chronic rejection

Late presentation (mths-years)

Indolent but progressive allograft injury

Usually irreversible

Difficult to treat if not caught early

Eventually result in failure of most vascularized solid organ allograft

But the Liver is special!

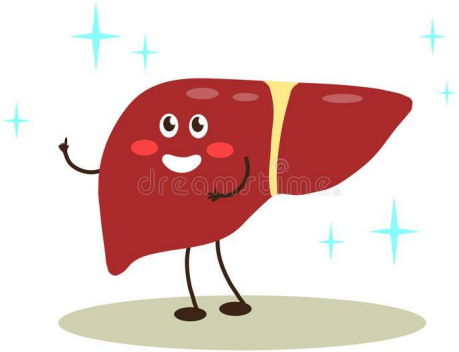

Incidence of CR 3-17%

At 5yrs post op:

only 4-8% of LT go into CR



In LT – potentially reversible

Due to unique immunobiological properties and regenerative capacity of main targets of CR – bile ducts

Chronic rejection : Clinical Presentation

- Hx of acute rejection
- Develops progressive cholestasis + increased canalicular enzymes
- Unresponsive to usual anti-rejection treatment
- Symptoms (if present) similar to acute cellular rejection (ACR)
- **<u>Typically, 3 clinical settings:</u>**
  - End of unresolved ACR
  - Multiple episodes of ACR
  - Evolving without preceding clinically recognized ACR episodes
    - Inadequate immunosuppression – due to non-compliance, infection, neoplastic or toxicity of immunosuppression therapy

Risk factors for CR

Jain et al. (2001) study of 32 pts with biopsy proven CR post LT found:

- Incidence of acute rejection (> 3 episodes of ACR noted in 25% of pts)
- Mean donor age (43 ± 14.7yrs)
- Initial diagnosis of PBC, PSC, or AIH (RR = 4.3)
- Hepatitis B or C (RR = 3.2)

- Steroid induction dose / CMV infection had no statistical significance

Chronic rejection is diagnosed by liver biopsy

- Histological grading of degree of portal, bile ducts and venous endothelial inflammation
- **Rejection activity index (RAI)**
  - 0-2 : no rejection
  - 3 : borderline
  - 4-5: mild
  - 6-7: moderate
  - 8-9: severe
- In CR:
  - **Progressive bile duct disappearance & obliterative arteriopathy, known as "ductopenia"**
  - **Less inflammatory**
- In late phase diffuse hepatic fibrosis occurs

1. Bile duct degenerative changes (early) → bile duct loss (late)
2. Foam cell obliterative arteriopathy

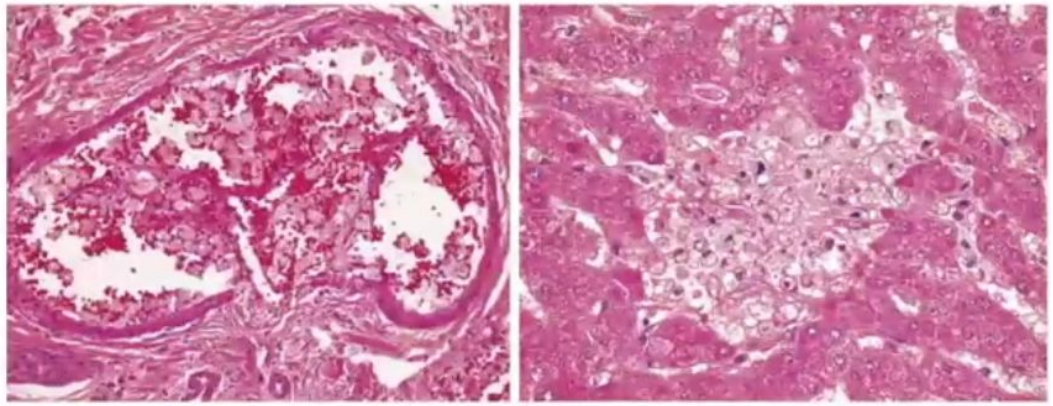

Kanel GC, Korula J. *Atlas of Liver Pathology*, 3rd ed. (2011)

NB: Prior to liver biopsy must exclude other causes of presentation

Treatment of CR

Early treatment can help to reverse CR

Non responders may need re-transplantation

Predictors of non-recovery of CR: at risk of re-transplantation

Both Jain et al. (2001) & Blakmor et al. (2000) found the following:

- Donor age (>40yrs)
- Presence of histological features :
  - more extensive bile duct loss,
  - small arterial loss,
  - presence of foam cell clusters
- Higher total bilirubin and AST level

Mission: Rescue the graft!

Escalation of immunosuppression

Use of mTOR inhibitors

Use of ATG

Escalation of immunosuppression

When CR diagnosed early: alterations in immunosuppression regimens can salvage the graft!

Optimization of immunosuppression by:

1. **Steroids** – Methyl pred pulse 500mg-1g/day for 3 days leads to 60-90% of ACR response in 1st round itself, hence used in CR
    - 10-15% may need another round
2. **Increase baseline immunosuppression:**
    - Increase Tac dose
    - Add another agent : MMF / mTOR inhibitors

Studies have shown that:

✔ Effectiveness of steroids rises if tacrolimus maintenance at higher levels

✔ MMF may be effective when serum bilirubin is low

✔ Can reverse CR, if intervene early – up to 60% of patients

(small studies with few experiences)

Use of mTOR inhibitors

Suppress cytokine mediated T cell proliferation
Act at a later stage in cell cycle than CNI
Can give in combination for synergistic effect
Anti-fibrosis effects
Anti-tumour effects – less malignancy

Sirolimus

- Neff et al (2003): 61.9% CR resolved by adding Sirolimus to Tac (N=21)
- FDA warning: excess mortality, graft loss, higher HA thrombosis
- Reserved for impaired renal function / pre transplant HCC

Everolimus

- Reduces angiogenesis
- Has shorter T1/2, with easy dose adjustment and less nephrotoxic
- But narrow therapeutic window 3-8ng/ml
- SE: Mild and transient thrombocytopenia, leukopenia, diarrhoea and high triglycerides

Evidence for Everolimus in CR

FDA (USA): (2013)

NICE (UK) : (2015)

Everolimus + reduced Tac dose approved for post LT immunosuppression:

Fewer episodes of rejection at 12, 24 & 36 mths,

Preserved renal function compared to Tac monotherapy

Everolimus monotherapy NOT recommended in early post LT - increased risk of rejection

Nielsen et al. (2011)

Everolimus as rescue therapy in pediatric LT recipients with chronic graft dysfunction (CGD)

4 out of 12 patients with CGD had normalized LFTs with everolimus

6 had partial improvement

2 no response.

Maintained trough levels at 4-6ng/ml (in combination with Tac)

Ueno et al. (2018)

Case series in use of Everolimus in CR in 2 paediatric LT recipeints

Everolimus effective in CR with Liver biopsy at 24mths:

- Restoration of bile ducts reduction of LFTs
- No progression of hepatic fibrosis

SE noted when trough level > 5ng/ml

Recommend trough level 3-5ng/ml (in combination with Tac)

Use of ATG (Anti thymocyte globulin)

- T cell depleting polyclonal antibody (Equine /Rabbit)
- rATG superior to eATG = in preventing ACR
- Effective in ACR after renal transplant – hence used in LT!
- Given as infusion 1.5mg/kg for 5-7 days in CR
- Several studies showed resolution of steroid resistant rejection with ATG (resolution rates 73-100%)

Reluctance to use as not always successful and has side effects :

  - Short term: Cytokine release syndrome, leukopenia and anaemia, CMV infection
  - Long term: HCV reactivation, opportunistic infections, malignancy (post-transplant lymphoproliferative disorder)

- Needs close monitoring , preferably in ICU setting

Any other agents?

IL-2 agents :

(Basiliximab / Daclizumab) thought to be beneficial - not efficacious, limited evidence

Has been used in steroid resistant ACR cases in place of ATG

Back to our patient……

Discussion with Rela Institute Transplant Unit -India

Add 0.5mg BD Everolimus –
to help rescue late rejection

Continue for 1 week and look for any plateauing of enzymes

Omit MMF

Continue Tac and steroids

If fail, try other options:

- ATG – not had good experience
- Re-transplant

3rd admission: 3/8/2021 - Pruritus with rising AST/ALT

	4/8	5/8	6/8	7/8	8/8	9/8	11/8	12/8	13/8	15/8	16/8	18/8	20/8	22/8	23/8	24/8	25/8	26/8	27/8	28/8	29/8
AST	**289**	**250**	**176**	**160**	**164**	**255**	**261**	**321**	**351**	**303**	**237**	**236**	**286**	**327**	**337**	**300**	**254**	**298**	**225**	**306**	**261**
ALT	**446**	**364**	**337**	**336**	**306**	**367**	**400**	**470**	**520**	**498**	**375**	**385**	**405**	**487**	**509**	**451**	**398**	**451**	**361**	**446**	**405**
ALP	138	119	99	112	121	107	92	117	133	110	127	129	125	142	134	123	109	123	114	133	105
GGT	316	255	246	261	254	273	290	334	385	351	292	311	364	427	440	354	410	373	309	453	356
ALB	3.1	2.7	2.6	2.8	2.6	2.4	2.4	3	3	2.8	3.7	2.9	2.8	3	3	2.7	2.7	2.6	2.3	2.8	3
GLOB	2.5	2.2	2	2.2	2.2	2.1	2	1.9	2.3	2.1	1.3	2.4	2	2.4	2.5	1.9	2.1	2.4	2	2.4	2.3
TB	**140.6**	**125.6**	**170.6**	**96.7**	**133.4**	**180.2**	**167.4**	**163**	**161.4**	**142.2**	**193.6**	**146**	**109.7**	**121.1**	**143**	**158.5**	**117.7**	**130**	**107.1**	**103.8**	**106.3**
DB	**107.5**	**96.9**	**129.7**	**128**	**103.3**	**125.5**	**87.4**	**103**	**149.7**	**109**	**121.5**	**143.3**	**85.3**	**91.3**	**133.6**	**83.8**	**91.9**	**64.9**		**69.3**	**57.6**
Cr	58	52	96	47	89	71	61		54	59	49	78	46	43	50	65	44	53		48	59
CRP	<5	<5	<5	7	<5	<2	<2		<5	8	<5	6	<2	<5	5	<5	<5	6	<5	6	
S. Na	137	137	133	134			135	136	135	135	137		133	135			132			136	
S. K	4.3	4.1	3.9	4.0			4.9	5.5	4.2	4.4	4.2		4.3	5			4.2			4	
INR	1.79	1.43	2.54	5.64	7.72	2.19	1.29	4.47	10.2	3.65	1.74	2.27	6.4		2.4			5.2	4.7		
Hb	11.5	12.4	11.5	11.7		11.34	11.5	13.0	13.1	11.9	10.8	11.5	11		11.7	11.4	10.9	12		11.8	
WBC	15.92	13.29	14.47	12.89		8.89	8.37	8.74	8.9	8.3	9.66	6.93	6.57		7.93	7.7	7.19	8.4		7.1	
PLT	183	191	186	194		183	223	187	257	182	180	173	171		152	140	151	166		161	

Methyl pred 1g pulse + NAC infusion given

Everolimus 0.5mg BD started

Prevention :Most Important in post LT care!

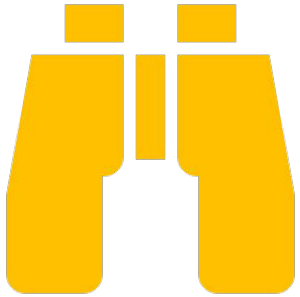

Vigilant monitoring for initial signs of rejection to provide early interventions

Improving compliance:

- **Early rejection – inadequate immunosuppression**
- **Late rejection – poor adherence, sparse monitoring**

Assess social circumstances :
finances / family support/ education/ limited daily structure/ depression all matter!

But younger, autoimmune liver disease, prior rejections have higher risks despite adequate monitoring and adherence

Summary

- Post LT Chronic rejection is an indolent but progressive allograft injury which can be reversible , if detected early.
- Commonly precipitated by inadequate immunosuppression – due to non-compliance, infection, neoplastic or toxicity of immunosuppression therapy
- Diagnosed via liver biopsy which would show dutopenia
- High dose steroids/ Methyl pred pulse are first line
- Low dose Everolimus can be added as rescue therapy in steroid resistant patients
- Despite resolution of steroid resistant rejection, ATG remains unpopular due to heavy side effect profile
- Prevention of rejection remains the most important factor in survival post LT

References

1. Demetris, A.J., Murase, N., Lee, R.G., Randhawa, P., Zeevi, A., et al. Chronic rejection. A general overview of histopathology and pathophysiology with emphasis on liver, heart and intestinal allografts. Ann Transplant 1997;2(2):27-44

2. Choudhary NS, Saigal S, Bansal RK, Saraf N, Gautam D, Soin AS. Acute and Chronic Rejection After Liver Transplantation: What A Clinician Needs to Know. *J Clin Exp Hepatol*. 2017;7(4):358-366.

3. Harrington CR, Yang GY, Levitsky J. Advances in Rejection Management: Prevention and Treatment. Clin Liver Dis. 2021 Feb;25(1):53-72.

4. Jain A, Demetris AJ, Kashyap R, Blakomer K, Ruppert K, Khan A, et al. Does tacrolimus offer virtual freedom from chronic rejection after primary liver transplantation? Risk and prognostic factors in 1,048 liver transplantations with a mean follow-up of 6 years. Liver Transpl. 2001;7:623-30.

5. Neff G, Montalbano M, Slapak-Green G, et al: A retrospective review of sirolimus (Rapamune) therapy in orthotopic liver
transplant recipients diagnosed with chronic rejection. LiverTranspl 9:477, 2003

6. Nielsen, D., Briem-Richter, A., Sornsakrin, M., et al., The use of everolimus in pediatric liver transplant recipients: first experience in a single center. Pediatr Transplant, 2011. 15151515(5): p. 510

7. Ueno T, Kodama T, Noguchi Y, Deguchi K, Nomura M, Saka R, Watanabe M, Tazuke Y, Bessho K, Okuyama H. Safety and Efficacy of Everolimus Rescue Treatment After Pediatric Living Donor Liver Transplantation. Transplant Proc. 2020 Jul-Aug;52(6):1829-1832.

8. Lee SG, Jeng LB, Saliba F, Singh Soin A, Lee WC, De Simone P, Nevens F, Suh KS, Fischer L, Jin Joo D, Fung J, Joh JW, Kaido T, Grant D, Meier M, Rauer B, Sips C, Kaneko S, Levy G. Efficacy and Safety of Everolimus With Reduced Tacrolimus in Liver Transplant Recipients: 24-month Results From the Pooled Analysis of 2 Randomized Controlled Trials. Transplantation. 2021 Jul

9. Bzeizi KI, Smith R, Albenmousa A, Dama M, Aba-Alkhail F, Jalan R, Broering D. Long-Term Outcomes of Everolimus Therapy in De Novo Liver Transplantation: A Systematic Review and Meta-Analysis of Randomized Controlled Trials. Transplant Proc. 2021 Jan-Feb;53(1):148-158.

10. Rodríguez-Perálvarez M, Guerrero-Misas M, Thorburn D, Davidson BR, Tsochatzis E, Gurusamy KS. Maintenance immunosuppression for adults undergoing liver transplantation: a network meta-analysis. *Cochrane Database Syst Rev*. 2017;3(3):CD011639. Published 2017 Mar 31. doi:10.1002/14651858.CD011639.pub2

11. Schmitt TM, Phillips M, Sawyer RG, Northup P, Hagspiel KD, Pruett TL, Bonatti HJ. Anti-thymocyte globulin for the treatment of acute cellular rejection following liver transplantation. Dig Dis Sci. 2010 Nov;55(11):3224-34.

12. Lee JG, Lee J, Lee JJ, et al. Efficacy of rabbit anti-thymocyte globulin for steroid-resistant acute rejection after liver transplantation [published correction appears in Medicine (Baltimore). 2016 Jul 18;95(28):e0916]. *Medicine (Baltimore)*. 2016;95(23):e3711.

13. Blakolmer K, Jain A, Ruppert K, Gray E, Duquesnoy R, Murase N, et al. Chronic liver allograft rejection in a population treated primarily with tacrolimus as baselineimmunosuppression: long-
term follow-up and evaluation of features for histopathological staging. Transplantation. 2000;69:2330-6.

Any Questions?